

Acne/PFB

Demographics (as above)

Clinical History:

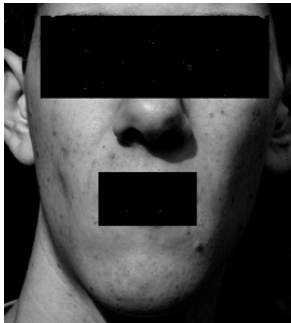- Reason for consultation: diagnosis, confirmation of diagnosis, recommendations for management, assumption of care, medical evaluation, hospitalization evaluation, disposition/duty status question, treatment recommendations, other _____
- Duration: months, years, unknown, other _____
- Prior acne treatment, including OTC, duration of therapy
- Lesions on chest and back?
- Scarring?
- If female of childbearing potential, method of contraception
- For PFB patients, shaving history, previous treatments and results
- Provisional diagnosis

Images Suggested:

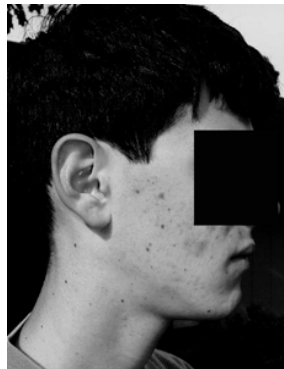- A: Not usually needed because the condition is usually localized to the face, neck, and trunk
- B: Reference views of the face (e.g. full face or right and left profiles), view of upper back or chest (if necessary)
- C: Images to demonstrate lesions that are characteristic for this particular patient (i.e. comedones, pustules, cysts, scarring etc)

Sample images:

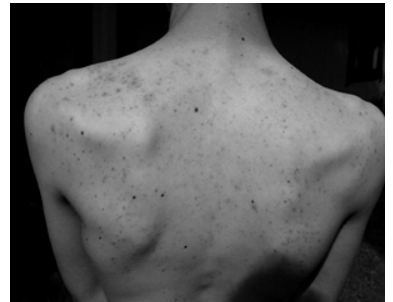- A. None required because the acne is confined to the face and upper back.
- B. Regional Views: AP Face, Right Lateral Face, PA Back



AP View of
the Face

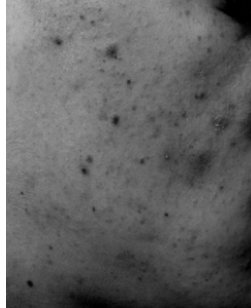


Right Lateral
View of the Face

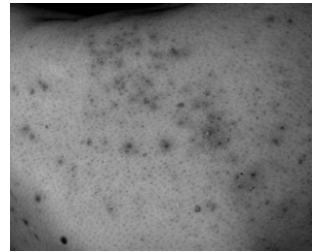


PA View of
the Back

- C. Close Up Views: Right Lateral Face and PA Back (note effect of oblique external incandescent lighting to accentuate details of texture and topography)



Close up, Right lateral face



Close up, PA view, upper back